ISSN: 2458-8989

Natural and Engineering Sciences

NESciences, 2026, 11 (3): 768-776 doi: 10.28978/nesciences.263060

Histomorphological and Cellular Characteristics of Thin Endometrium Associated with Female Infertility

Zaripova Dilnoza[1], Djumayeva Feruza[2], Sultonova Nigora Azamovna[3], Kurbaniyazova Madina[4], Djurabekova Surayyo[5], Karimova Feruza[6]

[1] DSc, Associate Professor, Head of the Department of Simulation-Based Training, Bukhara State Medical Institute named after Abu Ali ibn Sino, Bukhara, Uzbekistan. Email: zaripova.dilnoza@bsmi.uz; zaripovadilnoza89@gmail.com, ORCID: 0000-0003-0736-5654

[2] Independent Researcher, Bukhara State Medical Institute named after Abu Ali ibn Sino, Bukhara, Uzbekistan. Email: feruzakhonim56@gmail.com, ORCID: 0009-0008-2860-7943

[3] DSc, Associate Professor, Department of Retraining and Advanced Training of Family Physicians, Bukhara State Medical Institute named after Abu Ali ibn Sino, Bukhara, Uzbekistan. Email: sultonova.nigora@bsmi.uz; nigorasultonova8788@gmail.com, ORCID: 0009-0009-1397-0325

[4] Department of Obstetrics and Gynecology, Oncology, Urgench State Medical Institute, Urgench, Uzbekistan. Email: dr.madina240884@gmail.com, ORCID: 0000-0001-9082-2865

[5] Department of Obstetrics and Gynecology, Pediatric Gynecology, Tashkent State Medical University, Tashkent, Uzbekistan. Email: dzurabekovasurayo@gmail.com, ORCID: 0000-0003-3720-2370

[6] Department of Clinical Subjects 2, Asia International University, Bukhara, Uzbekistan. Email: karimova.feruza@oxu.uz, ORCID: 0009-0008-5021-0029

Abstract

Thin endometrium is associated with impaired endometrial receptivity and reduced implantation potential. This study aimed to assess morphological and immunohistochemical features of the endometrium in women with risk factors for thin endometrium and uterine-factor infertility. The manuscript reports an examination of 135 women aged 25–40 years allocated to a control group (n=40), a group with early manifestations of thin endometrium (n=45), and a group receiving screening and corrective therapy (n=50). Endometrial thickness was assessed by transvaginal ultrasonography; tissue samples were examined histologically and by immunohistochemistry for estrogen receptor (ER), progesterone receptor (PR), Ki-67, and CD56. Pinopodial number and maturity were assessed, and immunostaining was evaluated using an H-score. Abundant pinopodia were reported in 92.5% of controls, compared with 6.7% and 8.0% in the second and third groups, respectively. Mature pinopodia were reported in 95.0% of controls, 2.2% of the second group, and 6.0% of the third group. The text also describes low or focal expression of CD56, Ki-67, ER, and PR in the illustrated endometrial samples. These findings suggest an association between altered pinopodial development, reduced expression of selected markers, and impaired endometrial receptivity. The group-level immunohistochemical results and the relationship between treatment and outcomes require clearer quantitative presentation.

Keywords: Thin endometrium; uterine factor infertility; endometrial receptivity; pinopodia; immunohistochemistry.

Corresponding Author: Zaripova Dilnoza, E-mail: zaripova.dilnoza@bsmi.uz

Available Online: 10/09/2026

Introduction

Thin endometrium remains one of the most challenging and insufficiently understood conditions in reproductive medicine. Despite continuous advances in assisted reproductive technologies (ART), implantation failure and unsuccessful in vitro fertilization (IVF) cycles are frequently associated with impaired endometrial receptivity. Recent studies indicate that infertility associated with thin endometrium accounts for approximately 8–14% of cases, whereas implantation failure related to inadequate endometrial receptivity reaches nearly 30%. During ART cycles, an endometrial thickness of less than 7 mm is observed in approximately 10% of patients. Furthermore, several studies have demonstrated that an endometrial thickness below 7 mm is associated with at least a twofold increase in the risk of miscarriage. Although numerous studies have investigated this condition, there is still no universally accepted consensus regarding its diagnosis and treatment, emphasizing the need for further investigation of its clinical, morphological, immunological, and molecular mechanisms (Xramczova & Bashmakova, 2019; Negmatullaeva et al., 2024; Kasius et al., 2014; Lee et al., 2016; Zaripova et al., 2024; Liu et al., 2019).

Among the various causes of female infertility, uterine factor infertility associated with thin endometrium is one of the most common. The endometrium is a highly specialized tissue characterized by remarkable sensitivity to cyclic hormonal changes. This property is essential for the establishment of the implantation window and for maintaining early pregnancy. Successful embryo implantation depends primarily on adequate endometrial receptivity, including the formation of mature pinopodes during the implantation window. Consequently, considerable research efforts have focused on identifying the mechanisms responsible for impaired endometrial receptivity and discovering reliable biomarkers that could improve reproductive outcomes (Martins et al., 2020; Ashurova & Bobokulova, 2024; Mahutte et al., 2022; Kumbak et al., 2009; Kunicki et al., 2014).

According to the recommendations of the European Society of Human Reproduction and Embryology (ESHRE), the principal mechanisms underlying thin endometrium include impaired synchronization between the endometrium and the menstrual cycle, reduced uterine perfusion, defective vascularization, fibrotic remodeling, and immune dysregulation. Disturbances in endometrial blood flow have been confirmed by Doppler ultrasound studies demonstrating abnormal uterine hemodynamics in women with implantation failure. Most investigators agree that an endometrial thickness of at least 8 mm provides optimal conditions for embryo implantation (Wu et al., 2023; Mahajan & Sharma, 2016; Mouhayar & Sharara, 2017; Wang et al., 2020).

Persistent inflammatory processes, endothelial dysfunction, impaired microcirculation, oxidative stress, and abnormalities of local immune regulation also play a significant role in the pathogenesis of thin endometrium. These pathological changes contribute to progressive degeneration and atrophy of the functional endometrial layer, resulting in decreased receptivity even after successful treatment of the underlying inflammatory condition. Endometrial transformation is regulated through complex interactions among steroid hormones, cytokines, growth factors, and immune cells, ultimately determining the establishment of a receptive endometrium and successful embryo implantation.

Material and method

To investigate the morphological and immunohistochemical mechanisms underlying the development of thin endometrium, evaluate alterations in endometrial receptivity, and develop pathogenetically justified approaches for improving the reproductive potential of women with uterine factor infertility.

H-score= (1×% weak coloration) + (2×% moderate coloration) +
(3×% strong color)

The immunohistochemical expression of receptors in the glandular epithelium and endometrial stroma was evaluated by analyzing at least 10 randomly selected visual fields with a ×400 magnification. For each studied drug, the percentage of immunopositive cells and the intensity of their staining were determined. The expression of estrogen (ER) and progesterone (PR) receptors was evaluated based on the presence of a specific nuclear dye in the cells. VEGF expression was assessed by the degree of coloration of glandular epithelial cells, stromal elements, and trophoblast cytoplasm, and the percentage of immune-positive cells and the intensity of the immunohistochemical reaction were determined. The final evaluation of expression was conducted using the semi-quantitative H-score calculation method. CD56 expression was determined by the presence of specific decidual membrane staining.

In-depth studies will be conducted on a cohort of 135 women with risk factors for the development of thin endometrium (TE). The distribution of women into groups will be carried out taking into account age characteristics, harmful habits, somatic diseases, and history of bone fractures. The first group will include 40 women in the active reproductive period, and the second group will include 45 women with early clinical manifestations of TE who have not undergone preventive drug therapy. The third group will consist of 50 patients who will undergo screening and corrective therapy.

Statistical processing of the research results was conducted using modern methods of variational statistics. Data analysis was performed using IBM SPSS Statistics (version 27.0) and Microsoft Excel 2021. Before conducting the comparative analysis, the nature of the distribution of quantitative data was assessed using the Shapiro-Wilk criterion. With normal distribution, the results were represented as the arithmetic mean and standard deviation (M±SD), while with abnormal distribution, they were represented as the median and interquartile range (Me [Q1; Q3]).

To compare quantitative indicators between two independent groups, Student's t-test was used with normal distribution, and Mann-Whitney's U-test was used in the absence of normal distribution. To compare indicators before and after treatment in the same group, the paired Student's t-test or Wilcoxon's test were used. When comparing three or more independent groups, one-factor variance analysis (ANOVA) was applied, followed by post-hoc analysis or the Kraskel-Wallis criterion depending on the nature of the data distribution. Qualitative indicators are presented as absolute values and percentages (n, %). To assess differences between categorical features, the $\chi 2$ (Pearson) criterion was used, and for an expected frequency of less than 5, the exact Fisher criterion was used. To determine the relationship between quantitative indicators, the Pearson (normal distribution) or Spearman (non-normal distribution) correlation coefficient was calculated. Differences were considered statistically significant at a significance level of $p < 0.05$. All studies were conducted in accordance with the rules of the ethics committee of the Bukhara State Medical Institute. Written voluntary consent was obtained from all patients before all procedures were performed, and all possible consequences of the applied research and treatment methods were explained to them.

Results

The conducted study involved women of reproductive agem from 25 to 40 years old. Their average age in the control group was 30.1±3.5 years, in the second group 31.4±3.8 years, and in the third group 32.5±3.9 years ($p>0.05$). The women in the control group did not have infertility or a complicated obstetric and gynecological history. Sterility lasted from 1.5 to 5 years, averaging 3.25±0.8 years in the groups. In groups, it was 2.9±0.7 years in the second group and 3.5±1.0 years in the third group. The data are shown in Figure 1.

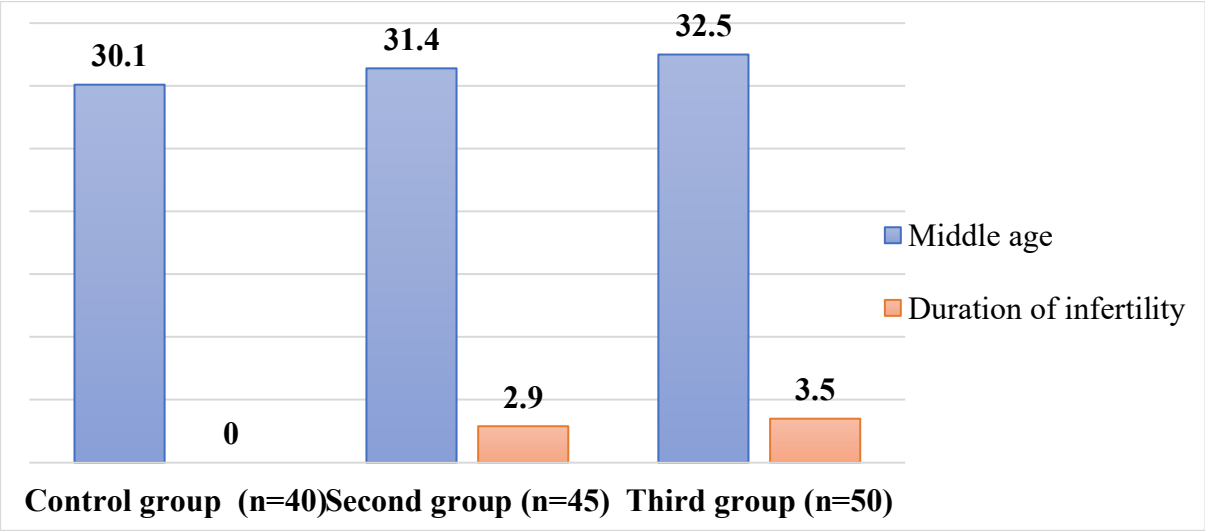

Figure 1. Average age of patients and infertility duration in the study groups, n=135

We know that the main indicator of successful implantation is the level of pinopodium. In women with hypoplasia, the number of pinopodia is low, which hinders the successful implantation of the embryo. The number of pinopodiums was assessed as the abundance of pinopodiums and the small number, the absence of pinopodiums. And in terms of maturity, mature and immature pinopodiums. Information related to this criterion before treatment is provided in Table 1.

Table 1. Criterion for evaluating pinopodias in the study groups before treatment, n=135

Assessment of Pinopodium Number and Maturity	First control group, (n=40)		Second group, (n=45)		Third group, (n=50)		P
	абс	%	абс	%	абс	%	
Abundance of pinopodiums	37	92,5	3	6,7	4	8,0	p<0,001
A small number of pinopodiums	3	7,5	40	88,8	41	82,0	p<0,001
Absence of pinopodium	0	0	2	4,44	5	10	p<0,05
Mature pinopodiums	38	95	1	2,22	3	6,0	p<0,001
Immature pinopodiums	2	5	42	93,3	42	84,0	p<0,001

When analyzing Table 1 above, it can be seen that compared to the control group, the number of mature pinopodiums in the main groups has a very large range of difference, which in the second group was even more pronounced compared to all groups. At the same time, in almost 92.5% of cases, an abundance of pinopodium was noted only in the control group, whereas in other groups, it was only 3 (6.7%) and 4 (8.0%) cases, respectively ($p<0.001$).

The next criterion—the small number of pinopodiums—had a reverse trend, where it was noted more frequently in the main groups compared to the control group. Detailed analysis shows that in the second and third groups, it was noted in 40 (88.8%) and 41 (82.0%) cases, whereas in the first control group, it was noted in 3 (7.5%) examined individuals, which was 13.3 and 13.7 times higher.

The complete absence of pinopodium was not observed only in the control group, whereas in the second group it was 2 (4.4%), and in the third group it was 5 (10.0%).

Assessment of the degree of pinopodial maturity showed that in 38 (95.0%) women of the control group, it corresponded to the norm, while in the second and third groups, it corresponded to the norm only in 1 (2.2%) and 3 (6.0%) patients, respectively ($p<0.001$).

While immature pinopodias were identified in the second group in 42 (93.3%), and in the third group in 42 (84.0%), the smallest amount of this parameter was noted in the control group, where it was 2 (5.0%) cases ($p<0.001$). From the analysis of the table above, it can be concluded that in the main groups, the number of immature pinopodiums and their absence was significantly higher compared to the control group, which may indicate the ineffectiveness of possible embryo implantation and reduce the risk of pregnancy. To confirm why this occurs, it is necessary to further study immunohistochemical markers and present the histological picture of patients with uterine forms of infertility.

Discussion

Immunohistochemical analysis of endometrial samples during the secretion phase of the cycle showed that these types of patients exhibited a low level of proliferative activity, manifested by low expression of proliferation markers ER, PR, Ki-67, and CD-56.

The expression level of CD-56 in patients with thin endometrium and uterine forms of infertility showed a low content of natural uterine killers, which are very important for maintaining local immune homeostasis in the endometrium. When the expression of this marker decreases, the remodeling process of uterine vessels deteriorates, which contributes to the improvement of blood flow due to the onset of pregnancy. Its insufficiency can lead to both unsuccessful implantation and early spontaneous miscarriage of the embryo during early gestational periods. It is typically used to diagnose immunological disorders in patients with thin endometrium and infertility. An example of CD-56 expression in a patient with 4-year infertility due to thin endometrium is shown below in Figure 1.a with a 100-fold increase and in Figure 1.b with a 400-fold increase.

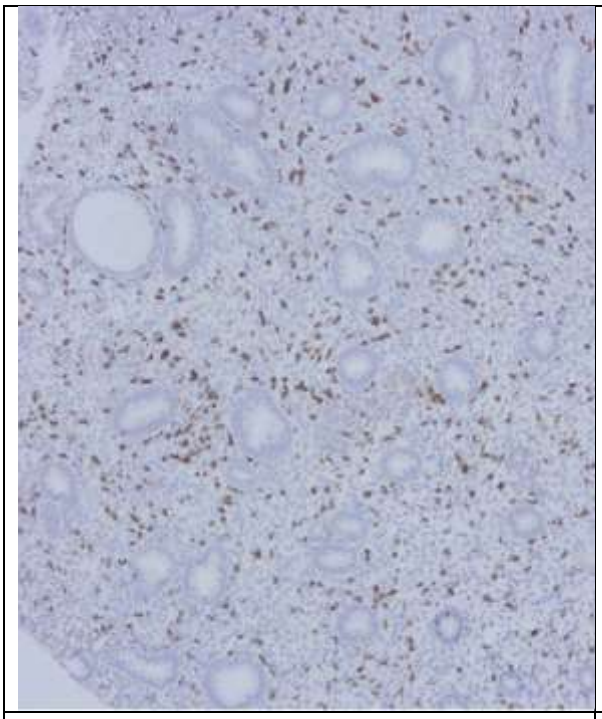

Fig. 1a) Immunohistochemical marker CD-56 in a 100-fold increase. Ok10xOb10. Staining DAB-chromogen

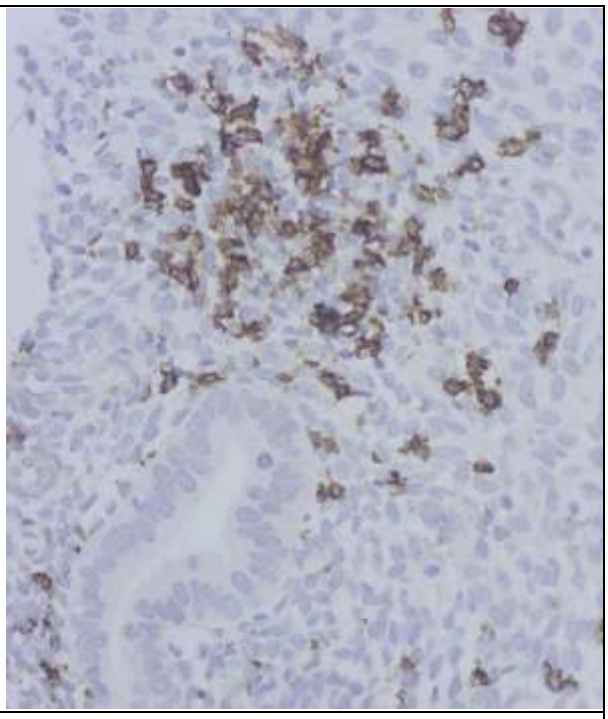

Fig. 1b) immunohistochemical marker CD-56 in 400-fold increase. Ok10xOb40. DAB chromogen color

Based on the aforementioned figures 1-a and 1-b, it can be concluded that in patients with infertility due to thin endometrium, the expression of this immunohistochemical marker is reduced. Even with different magnifications of 100 and 400 times, it can be seen that the number of positive express points accounted for more than 25% of the entire surface of the studied area. Negative cells accounted for 75%. Even with the intensity of core staining, it had a moderate degree of staining of 2+. According to the H-score scale, it was 40 points, which corresponds to low-moderate expression of CD56. According to the Allred scale, it showed an 11-33% proportion of positive cells, and the intensity of the nucleus color was 2+, which is a moderate color. When summing 3+2=5 points on the Allred scale, 5 out of 8 points, average degree of expression.

The next marker for study was the main immunohistochemical indicator of Ki-67 proliferation. This indicator was studied during the secretory phase of the menstrual cycle by taking biopsy tubes from endometrial tissue in patients with infertility lasting several years, where proliferative activity was evaluated.

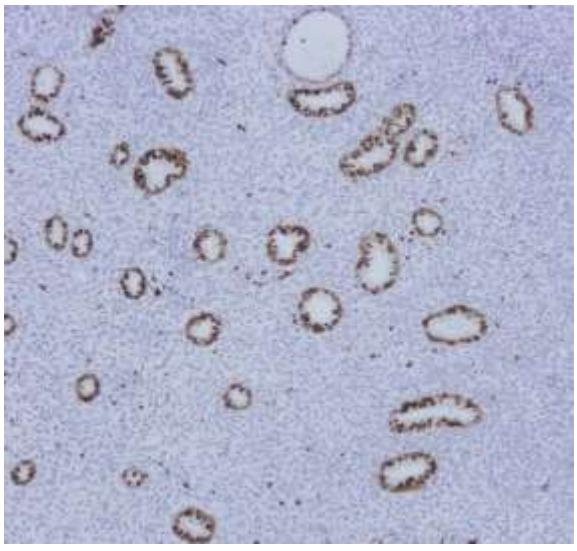

Fig. 2a) Immunohistochemical marker Ki-67 in a 100-fold increase. Ok10xOb10. Staining of DAB-chromogen

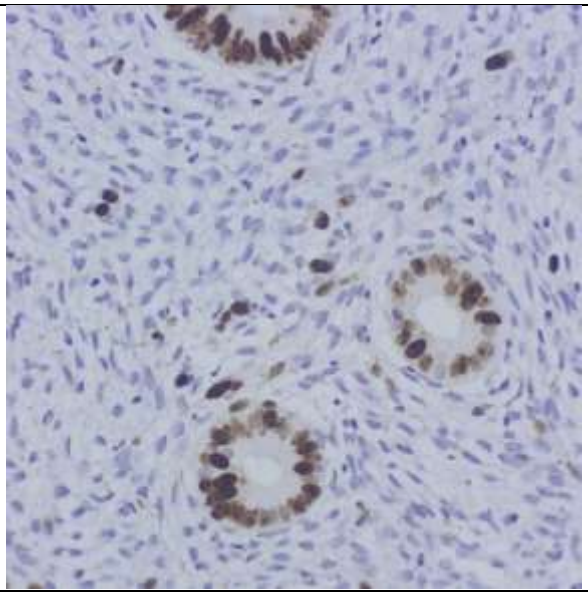

Fig. 2b) immunohistochemical marker Ki-67 in 400-fold increase. Ok10xOb40. DAB chromogen color

Immunohistochemical determination of the endometrial proliferation marker Ki-67 manifests as a decrease in cell division activity in the glandular epithelium and stroma. Normally, it promotes endometrial regeneration after menstruation. However, its insufficient expression leads to insufficient endometrial proliferation and a decrease in the number of pinopodia, which hinders successful embryonic niding. Based on the aforementioned Figures 2) a and 2) b, it can be concluded that in a patient with about 4 years of infertility, the Ki-67 marker was detected in only 30% of epithelial cells and 65% of nuclear cells. We identified positive expression in epithelial cells and negative expression in nuclear cells. The degree of core coloration was 2+, which is considered average. Semi-quantitative assessment on the Allred scale showed that the color intensity was 2+, and the degree of nuclear coloration was also 2+, with a sum of 2+2=4, which corresponds to medium-low expression of this marker, confirming low proliferative activity. According to the H-score scale, its expression was 70 points, which was calculated as follows: H-score = (8×1) + (10×2) + (14×3) = 70 points. According to numerous data, it is known that in the secretory phase of the cycle, the degree of expression of this marker should decrease under the influence of the hormone progesterone, but in our patients, we noted a clear low proliferative activity of the Ki-67 marker, which led to insufficient endometrial growth.

The next criterion for determining the immunohistochemical reaction of the endometrium was the ER marker, which in our study was reacted with rabbit antibodies and stained with DAB-chromogen dye under magnification of 100 and 400 times (Figures 3a, 3b).

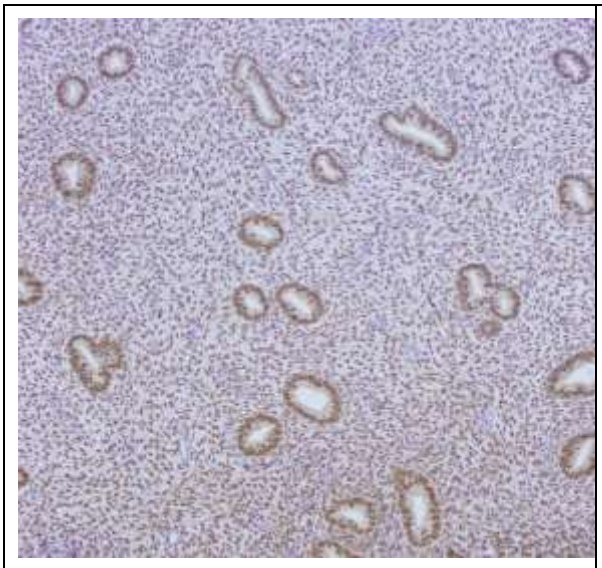

Fig. 3a) immunohistochemical marker ER in a 100-fold increase. Ok10xOb10. Staining DAB-chromogen

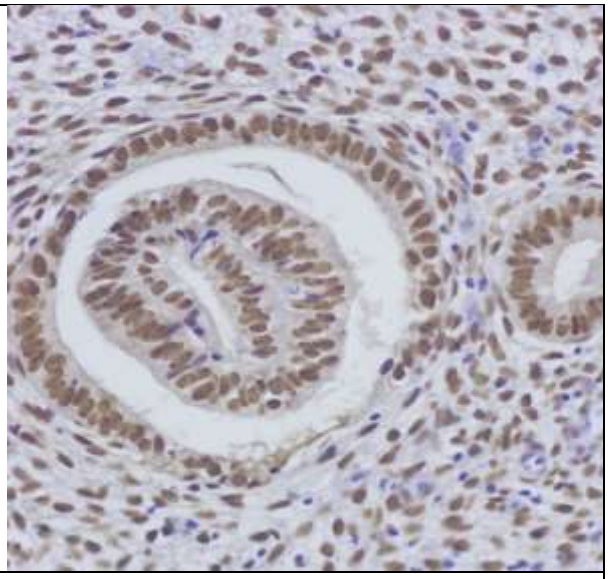

Figure 3b) immunohistochemical marker ER in 400-fold increase. Ok10xOb40. DAB chromogen color

Figures 3-a and 3-b show that the nuclear expression of this marker in the secretory phase of the cycle was determined in the glandular epithelial nucleus and in the stroma. For example, at a magnification of 100 times, it can be seen that uneven nuclear expression of estrogen receptors occurs in the nuclei. Positive expression is observed in the epithelial cells of the glands, while in the stroma, it is predominantly negatively colored. Sometimes we observe only focal positive expression. The main part of the glands is moderately colored, while the main part is not colored or has a negative coloration, which tells us about the low expression of this marker. Low estrogen levels lead to insufficient endometrial growth and low vascularization. At the same time, its level in epithelial cells was 2+ in intensity, which corresponds to moderate coloration, with positive cells accounting for 32%, and negative cells for 68%. In the stroma, the positive cells are even lower at 20%, the negative at 80%, and the color intensity is 1+, which is a weak color. Calculation using the H-score scale in the glandular epithelium showed that only 35% of the cells were stained. 35%x2=70% of the possible 300 indicates low ER expression. When calculating according to the Allred scale, it was established that the intensity of coloration in the glandular epithelium was 3+ (40%) and the degree of coloration was 2+, 3+2=5 points in total, which corresponds to a moderate average degree, which is insufficient for this phase of the cycle.

One of the main markers that should be evaluated in patients with thin endometrium to determine the degree of proliferation in the secretory phase of the cycle is the immunohistochemical marker PR (progesterone). Since the highest point of expression occurs during the secretion phase, normally this hormone is responsible for endometrial proliferation. Its insufficient quantity leads to insufficient

endometrial thickening and a low number of pinopodiums, which is of paramount importance for successful implantation. We studied the PR marker at 100 and 400 times magnification. Dyeing was performed using DAB-chromogen paint (Figures 4a, 4b). Positive PR expression in the glandular epithelial nucleus of the stroma was evaluated. In this figure, the positive coloration manifested as brown dots, which are predominantly focal in epithelial cells. In the stroma, a predominance of negative expression is noted, which is a marker of insufficient sensitivity to progesterone.

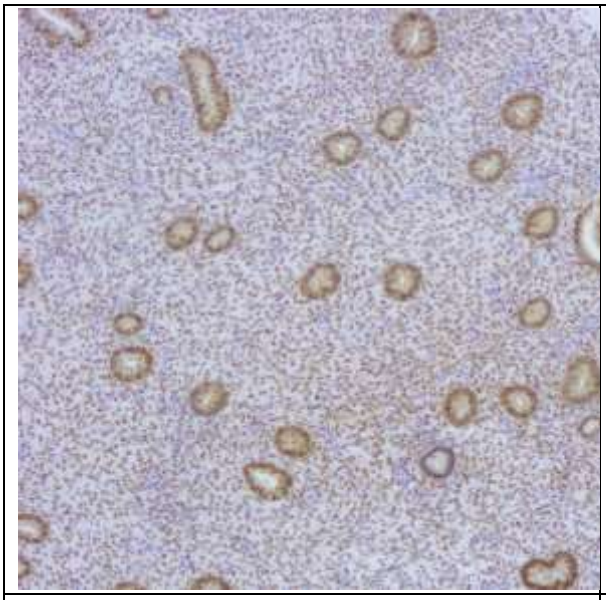

Fig. 4a) Immunohistochemical marker PR in a 100-fold increase. Ok10xOb10. DAB chromogen color

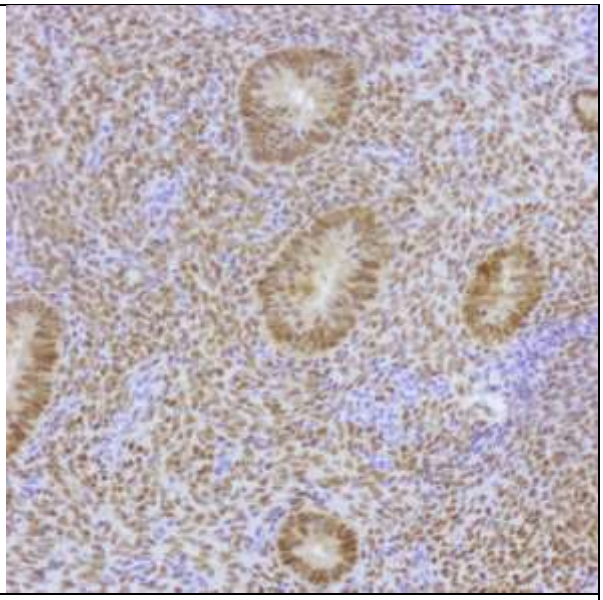

Fig. 4b) immunohistochemical marker PR in 400-fold increase. Ok10xOb40. DAB chromogen color

For example, the assessment of positive glandular epithelial expression was 30% and 70% of negative coloration. The color intensity was 2+ (moderate), the positive stroma component was 15%, and the negative one was 85%, with an intensity of 1+ (weak color). When evaluated by H-score, it was 30%x2=60% out of 300, which is considered a low level of expression. According to the Allred scale, the color intensity is 3+ (35%), and the core color level is 2+, totaling 3+2=5 points out of 8, which is an average level of expression that does not correspond to this phase of the cycle.

Conclusion

The results of this study showed that one of the important mechanisms for the occurrence of thin endometrium in the uterine form of infertility is the receptivity of the endometrium to the aforementioned markers. Insufficient expression of these markers leads to insufficient proliferation and a decrease in the number of pinopodia, which is the primary factor for successful embryo implantation. Taking into account the conducted analyses contributes to the development of an individual treatment plan for patients with thin endometrium, which leads to an increase in treatment success.

Author Contributions
All Authors contributed equally.

Conflict of Interest
The authors declared that no conflict of interest

Copliance with Ethical Standards
The manuscript states that written informed consent was obtained and that the study was approved by the local ethics committee of Bukhara State Medical Institute (Protocol No. 1, 2026). The authors should verify the exact committee name and approval details before submission.

References
1. Ashurova, N. G., & Bobokulova, S. B. (2024). Prediction of menstrual-ovarian cycle disorders in adolescent girls based on the study of genetic markers. Russian Bulletin of Obstetrician-Gynecologist, 24(5), 12–18. https://doi.org/10.17116/rosakush20242405112

2. Kasius, A., Smit, J. G., Torrance, H. L., Eijkemans, M. J., Mol, B. W., & Opmeer, B. C. (2014). Endometrial thickness and pregnancy rates after IVF: A systematic review and meta-analysis. Human Reproduction Update, 20, 530–541. https://doi.org/10.1093/humupd/dmu011
3. Kumbak, B., Erden, H. F., Tosun, S., Akbas, H., Ulug, U., & Bahceci, M. (2009). Outcome of assisted reproduction treatment in patients with endometrial thickness less than 7 mm. Reproductive BioMedicine Online, 18, 79–84. https://doi.org/10.1016/S1472-6483(10)60428-2
4. Kunicki, M., Lukaszuk, K., Woclawek-Potocka, I., Liss, J., Kulwikowska, P., & Szczyptanska, J. (2014). Evaluation of granulocyte colony-stimulating factor effects on treatment-resistant thin endometrium in women undergoing in vitro fertilization. BioMed Research International, 2014, 913235. https://doi.org/10.1155/2014/913235
5. Lee, D., Jo, J. D., Kim, S. K., Jee, B. C., & Kim, S. H. (2016). The efficacy of intrauterine instillation of granulocyte colony-stimulating factor in infertile women with a thin endometrium: A pilot study. Clinical and Experimental Reproductive Medicine, 43, 240–246. https://doi.org/10.5653/cerm.2016.43.4.240
6. Liu, K. E., Hartman, M., & Hartman, A. (2019). Management of thin endometrium in assisted reproduction: A clinical practice guideline from the Canadian Fertility and Andrology Society. Reproductive BioMedicine Online, 39, 49–62. https://doi.org/10.1016/j.rbmo.2019.02.013
7. Mahajan, N., & Sharma, S. (2016). The endometrium in assisted reproductive technology: How thin is thin? Journal of Human Reproductive Sciences, 9, 3–8. https://doi.org/10.4103/0974-1208.178632
8. Mahutte, N., Hartman, M., Meng, L., Lanes, A., Luo, Z.-C., & Liu, K. E. (2022). Optimal endometrial thickness in fresh and frozen-thaw in vitro fertilization cycles: An analysis of live birth rates from 96,000 autologous embryo transfers. Fertility and Sterility, 117, 792–800. https://doi.org/10.1016/j.fertnstert.2021.12.025
9. Martins, R. S., Oliani, A. H., Oliani, D. V., & de Oliveira, J. M. (2020). Continuous endometrial volumetric analysis for endometrial receptivity assessment on assisted reproductive technology cycles. BMC Pregnancy and Childbirth, 20, 663. https://doi.org/10.1186/s12884-020-03372-2
10. Mouhayar, Y., & Sharara, F. I. (2017). G-CSF and stem cell therapy for the treatment of refractory thin lining in assisted reproductive technology. Journal of Assisted Reproduction and Genetics, 34, 831–837. https://doi.org/10.1007/s10815-017-0922-6
11.Negmatullaeva, M. N., Tuksanova, D. I., & Zaripova, D. Ya. (2024). Structural-optical properties of blood serum and their role in predicting the development of osteoporosis in perimenopause. Russian Bulletin of Obstetrician-Gynecologist, 24(3), 71–76. https://doi.org/10.17116/rosakush20242403171
12.Wang, Y., Lyu, W., Xu, W., & Yu, Y. (2020). Asherman syndrome in adenomyosis treated with uterine artery embolization: Incidence predictive factors. La Radiologia Medica, 125, 437–443. https://doi.org/10.1007/s11547-020-01136-8
13.Wu, J., Huang, J., Dong, J., Xiao, X., Li, M., & Wang, X. (2023). The thicker the endometrium, the better the neonatal outcomes? Human Reproduction Open, 2023, hoad028. https://doi.org/10.1093/hropen/hoad028
14.Zaripova, D. Ya., Abdullaeva, M. A., Sultonova, N. A., Ahmedov, F. K., Nasirova, Z. S., Umurov, E. U., & Shukrullaeva, G. Zh. (2024). Optimization of diagnostic measures for early and premature menopause. Reproductive Health of Eastern Europe, 14(5), 617–628.
15. Abdulhassan AA, Hamid HH, Abood ZH, Al-Lami SM. Antifungal and antibiofilm effects of LL-37 against Candida albicans isolated from pregnant women with vulvovaginal candidiasis: impact on FKS1 gene expression. Natural and Engineering Sciences. 2026;11(3):66–78. doi:10.28978/nesciences.263006.
16. Kadim SA, Mohammed NT. Quercetin-enhanced immunostimulation by sonicated Salmonella typhimurium: a dual-action strategy. Natural and Engineering Sciences. 2026;11(2):12–19. doi:10.28978/nesciences.262002.
17.Al-Bedhawi MAA, Abood ZH, Ali RB. Evaluation of the gene/protein expression levels of the potential stem cells marker TMEM121 in Thy1 positive cells. Natural and Engineering Sciences. 2026;11(2):117–123. doi:10.28978/nesciences.262010.
18. Teshaev US, Aripova TU, Teshaev SJ, Yarbekov RR, Khamdamov BZ, Uktamova R. Development and validation of an immunoinflammatory biomarker model for predicting postoperative inflammatory responses: a molecular and biochemical approach. Natural and Engineering Sciences. 2026;11(3):97–107. doi:10.28978/nesciences.263009.
19.Jalalova VZ, Teshaev SJ, Sa'dulloyeva IK, Yuldasheva MM, Sharipova EM, Yuldasheva N. Protective effects of spirulina supplementation against exercise-induced cardiac remodeling: integrated morphological and biochemical evidence from an experimental study. Natural and Engineering Sciences. 2026;11(3):108–119. doi:10.28978/nesciences.263010.

20.Al-Hamadany AY, Taqi AH, Baker LAM, Gaddawi FY, Al Samarrai OR, Saadi AM. Antimicrobial activity and physiological effects of Echinacea-derived phenolic compounds in male albino rats. Natural and Engineering Sciences. 2026;11(3):163–177. doi:10.28978/nesciences.263015.
21.Teshaev SJ, Qodirov OO, Davlatov SS, Rakhmanov KE, Hamroyev IS, Rajabova NK. Morphometric and histological alterations in the spleen induced by chronic carbon monoxide exposure and the corrective effects of Gulimaxsar. Natural and Engineering Sciences. 2026;11(2):111–116. doi:10.28978/nesciences.262009.
22.Kosimov UU, Turniyozov AA, Bakhronov JD, Teshaev US, Khidirov ZE, Qodirov OO. Morphometric, histopathological, and immunohistochemical evaluation of myocardial remodeling in cisplatin-induced renal failure in rats. Natural and Engineering Sciences. 2026;11(3):132–141. doi:10.28978/nesciences.263012.